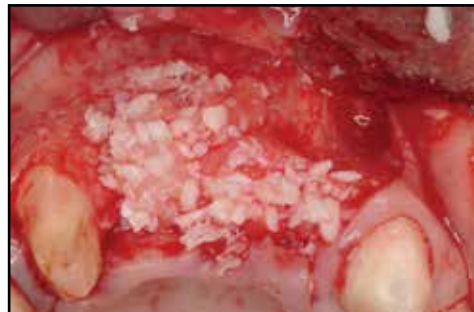

Advanced Surgical and Restorative Therapies Aimed at Rehabilitation of a Severe Dentoalveolar Defect in the Esthetic Zone

Barry P. Levin, DMD¹ • Sergio Rubinstein, DDS²

Hal Rosenthaler, DMD, FAGD³ • Toshi Fujiki, RDT⁴ • Peter Tawil, DDS, MS⁵

Abstract



This case report demonstrates 3-dimensional restoration of a severely-damaged alveolar ridge. Prior extraction, surgical trauma and infection resulted in total loss of facial and palatal cortices in an esthetically-critical area of the dentition. The compromised restorative and endodontic status of the adjacent canine precluded a conventional fixed bridge. Cytokine-enhanced stimu-

lation of mesenchymal stem cells, combined with a resorbable rigid scaffold reconstructed the alveolar ridge, facilitating implant placement. Additional grafting at implant placement provided the restorative dentist with two osseointegrated fixtures. The residual soft tissue deficiency was compensated for with ceramics combined with CAD/CAM technology to provide an esthetic fixed restoration.

KEY WORDS: Bone graft, growth factors, prosthetics, dental implants

1. Private practice Elkins Park, Pennsylvania, USA; Clinical Associate Professor, University of Pennsylvania; Dept. of Periodontology, Philadelphia, Pennsylvania, USA

2. Private practice Skokie, Illinois, USA

3. Clinical Assistant Professor, University of Pennsylvania, Dept. of Restorative Dentistry, Philadelphia, Pennsylvania, USA

4. Laboratory Director, Oral Rehabilitation Center, P.C., Skokie, Illinois, USA

5. Private practice, Beirut, Lebanon

INTRODUCTION

Tooth loss will predictably result in 3-dimensional loss of hard and soft tissue volume.^{1,2} Not only does this complicate the placement of implants according to the restorative treatment plan, but long-term hygienic complications can result from less than ideal fixture-positioning. When possible, many clinicians choose to place implants either at the time of extraction or shortly thereafter, attempting to minimize these complications.³ The literature contains numerous studies, case series and animal studies supporting this modality.^{4,5}

Often, extraction sockets are augmented to prevent much of this localized atrophy.^{6,7} When teeth are previously removed, these opportunities for earlier placement are lost, and often favorable hard and soft tissue volume has been lost as well. Reconstructive procedures exist to restore lost bone and soft tissue, providing the surgeon with an opportunity to place implants in restorable positions.^{8,9} Procedures including autogenous, allogeneic or xenogeneic block grafts, guided bone regeneration (GBR) with and without particulate bone grafts, rigid meshes and biologic mediators such as PRP, recombinant proteins, etc have been presented by surgeons.^{10,11} All of these modalities have the potential to regenerate alveolar bone capable of osseointegration.

A complication rarely reported in the literature, is what occurs when one of the above-mentioned procedures completely fails, and the resultant defect is more severe than the original one being treated. This case report describes the treatment of a 45 year-old female, who unsuccessfully underwent a regenerative procedure, which

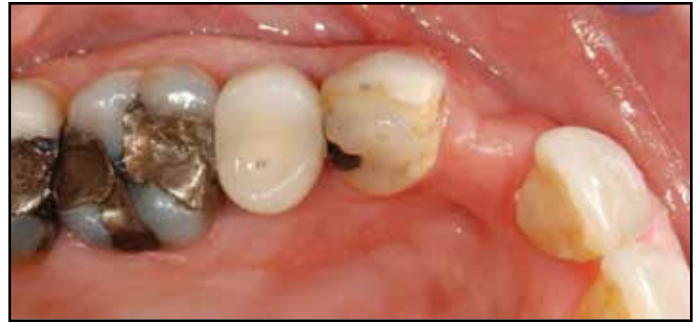

Figure 1: Clinical presentation of initial ridge defect in the maxillary anterior sextant.

became infected and led to the loss of significant alveolar bone and an additional tooth.

CASE REPORT

A 45 year-old female patient, with a history of smoking, presented to a private periodontal practice after experiencing an unsuccessful ridge-augmentation procedure at a university periodontal clinic. Originally, tooth #7 was surgically extracted and the socket was augmented. This procedure was not successful due to soft tissue complications and possibly smoking. She subsequently underwent a surgical procedure involving the use of a titanium mesh, combined with a bone allograft hydrated with rhPDGF-BB. Early exposure of the mesh and local site infection resulted in the removal of the mesh and debridement of non-incorporated bone graft materials. This resulted in a significant ridge-defect (Fig. 1). One of the titanium fixation tacks was left in place at this time. The patient was provisionalized from tooth #6 through #11 with a fixed restoration. Her general dentist determined tooth #8 to be non-restorable due to caries. She was referred to

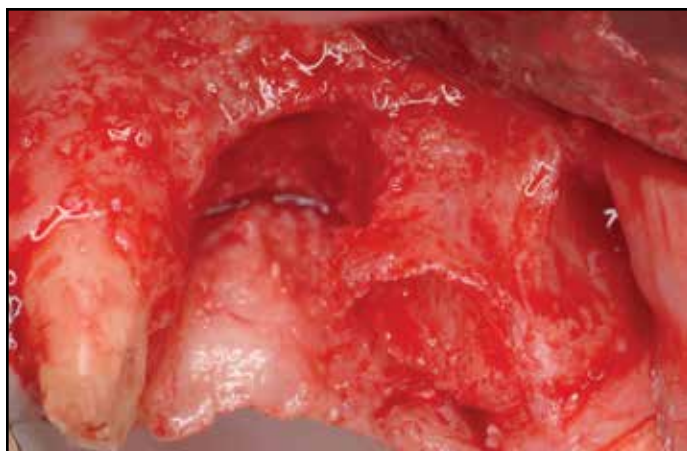

Figure 2: Following flap-reflection, extraction of the #8 root tip and removal of the retained tack, the loose, non-incorporated DBBM graft particles were debrided until a firm, bleeding osseous surface was identified.

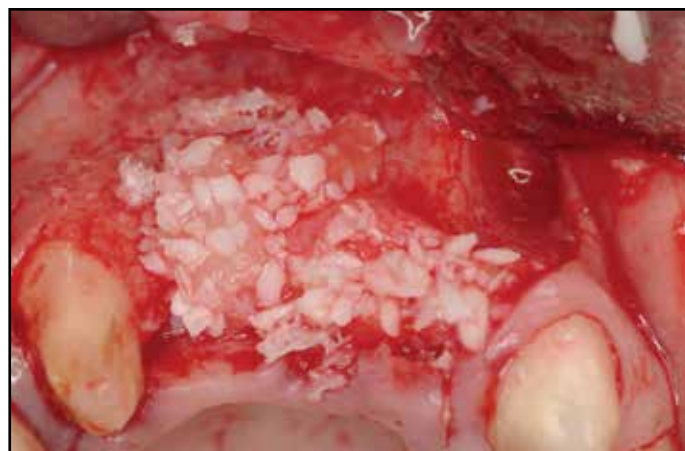

Figure 3: The 2-walled defect in the lateral incisor position, and the extraction socket of tooth #8 was obturated with a composite graft consisting of rhBMP-2/ACS and FDBA.

a private periodontal office for extraction of the carious central incisor and ridge-augmentation in the #7 and #8 locations. Previous endodontic therapy and guarded crown-to-root ratio of #6 was determined to be a questionable distal bridge abutment for a long-span fixed partial denture (FPD), and implant therapy was requested by the restorative dentist and patient.

The first surgery was geared towards extraction of the carious root of tooth #8, the removal of the fixation tack left behind by the previous surgeon and bone augmentation. The plan was to combine an osteoconductive, resorbable bone graft of FDBA (Life Net; Virginia Beach) with an osteoinductive graft of rhBMP-2/ACS (Infuse; Medtronic). One of the challenges presented was the lack of facial and palatal bone for vascularity and graft containment.

After reflection of a full-thickness mucoperiosteal flap, tooth #8 was carefully extracted, attempting to preserve the thin walls of the socket, the tack was easily removed and all

loose graft particles were debrided from the defect (Fig. 2). The rhBMP-2/ACS was prepared according to the manufacturer's specifications regarding soak-loading the absorbable collagen sponge (ACS) for at least 15 minutes prior to its application. Strips of various sizes were cut of the sponge and mixed homogeneously as possible with FDBA particles. This composite graft allowed uniform distribution of osteoinductive (rhBMP-2) and osteoconductive (FDBA) elements throughout the graft. After molding of this cohesive graft into the alveolus of #8 and the #7 defect (Fig. 3) a PLGA resorbable mesh (RapidSorb; Synthes) was warmed in a sterile water bath of 70 degrees Celsius and fixed with two resorbable screws consisting of the same PLGA material (Fig. 4). A connective tissue graft from the palatal flap was utilized to provide crestal coverage of the mesh and a facial periosteal releasing incision was performed to provide nearly-complete closure (Fig. 5).

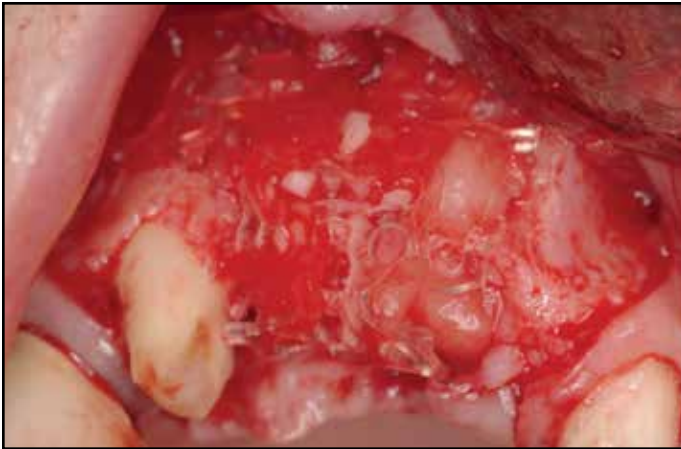

Figure 4: A resorbable PLGA mesh was thermoplastically-shaped based on a metal template extra-orally. It was then secured apically with two PLGA screws, providing graft-containment and stable 3-dimensional space-maintenance.

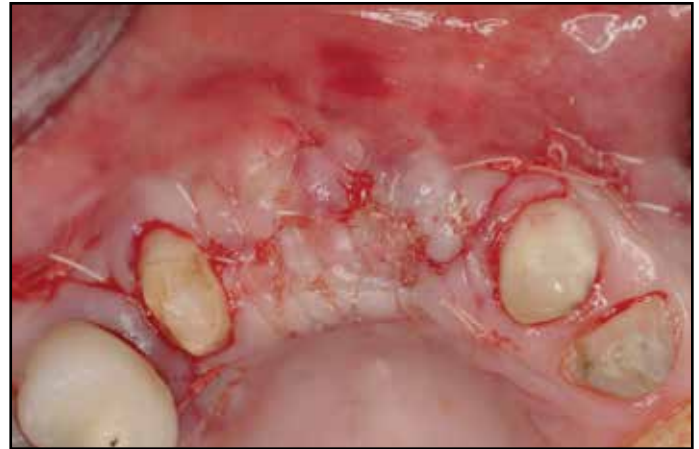

Figure 5: The thick palatal mucosa was thinned apically, maintaining blood-supply coronally and sutured to the facial flap, providing primary closure of the grafted site.

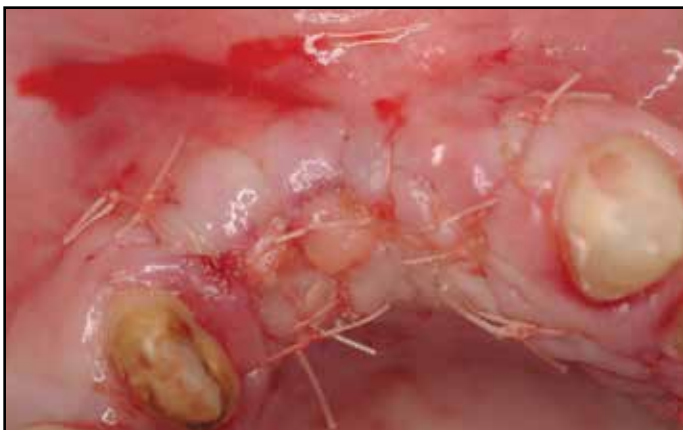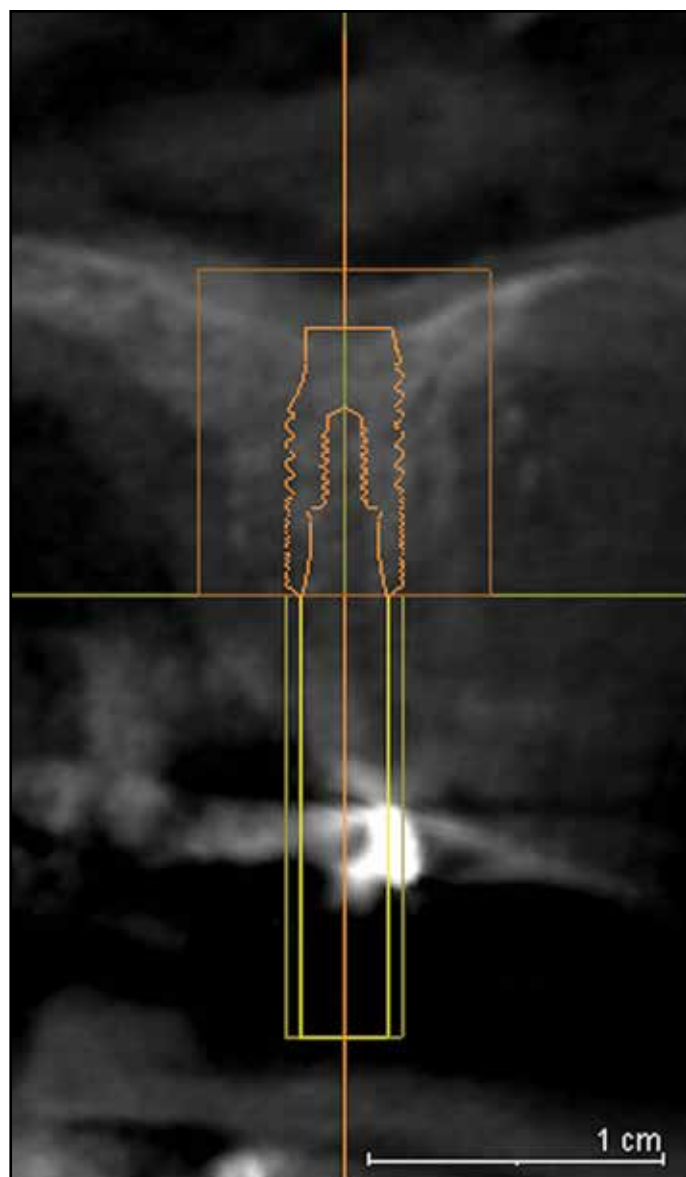
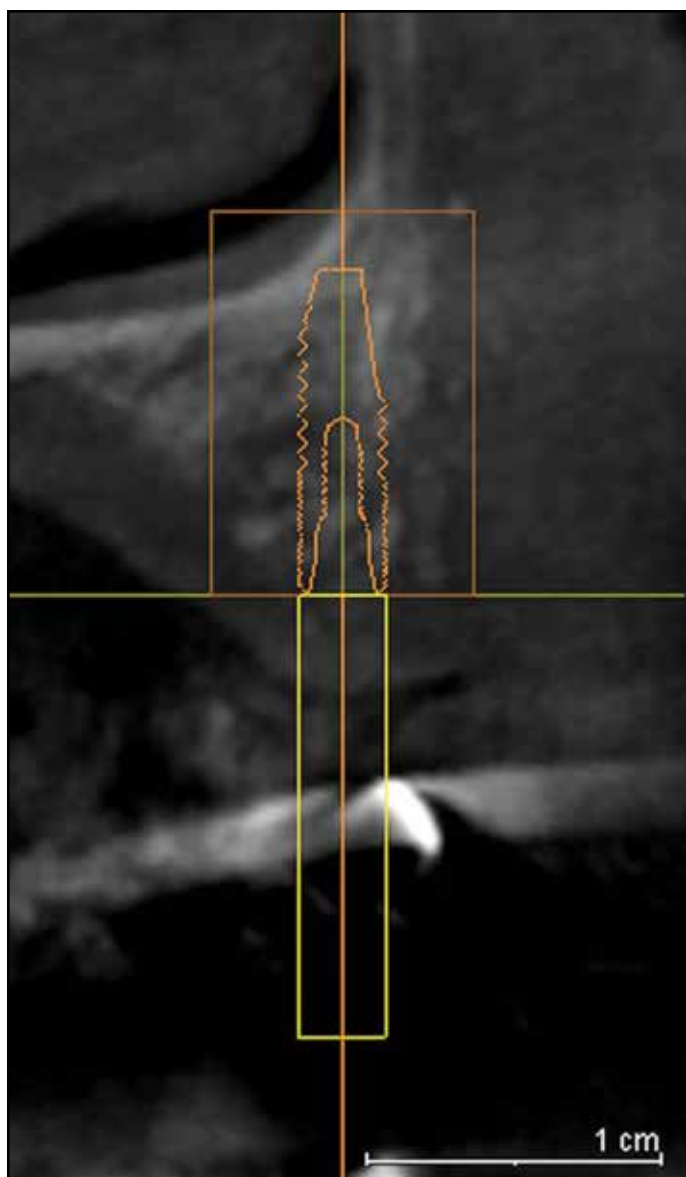


Figure 6: Approximately 4 months after hard tissue grafting, a soft tissue graft was secured from the palatal mucosa of the premolar region. This was done to increase the zone of keratinized mucosa and increase mucosal thickness.

Approximately four months after bone augmentation surgery, a subepithelial connective tissue graft was performed to increase the width and thickness of keratinized mucosa in the anticipated implant-placement sites (Fig. 6). At about 8 weeks following soft tis-

sue augmentation and 6 months after bone grafting, dental implant surgery was performed. Prior to surgery, a CBCT revealed significant hard tissue regeneration in the lateral and central incisor positions (Figs. 7A & 7B).

The regenerated height of the ridge measured between 8mm-9mm (Fig. 8). Facial-palatal width was determined to be adequate for implant placement of 3.0mm and 3.5mm implant diameters for the lateral and central incisors, respectively. The plan was to place the implants to the cortical base of the nasal floor and utilize the fixtures and healing abutments as “tent poles” to support the same composite bone graft used in the first procedure (Fig. 9). A large portion of the osteoinductive ACS was applied over the graft and 2.0mm tall healing abutments (Fig. 10), then an amnion-chorion membrane (BioXclude; Snoasis) was applied crestally to aid in soft tissue maturation (Fig. 11) and the site was closed with monofilament sutures (PTFE; Gore) (Fig. 12).



Figures 7a and 7b: Cross-sectional images of the proposed #7 and #8 implant sites from the CBCT taken approximately 6 months after bone grafting. Planning software is utilized to select implant sizes and positions.

After approximately 2 months healing, both healing abutments are partially-exposed. When the healing abutment on the #7 position implant was loosened, there was detectable movement of the implant fixture. The healing abutment was re-tightened. The #8 healing abutment was easily removed and a fixture level impres-

sion was taken. A screw-retained provisional restoration, supported by the single, central incisor implant was indirectly fabricated. An additional healing period of 8 weeks preceded utilization of this implant for fixation of the temporary restoration. During this time, a restorative post and core and new temporary crown

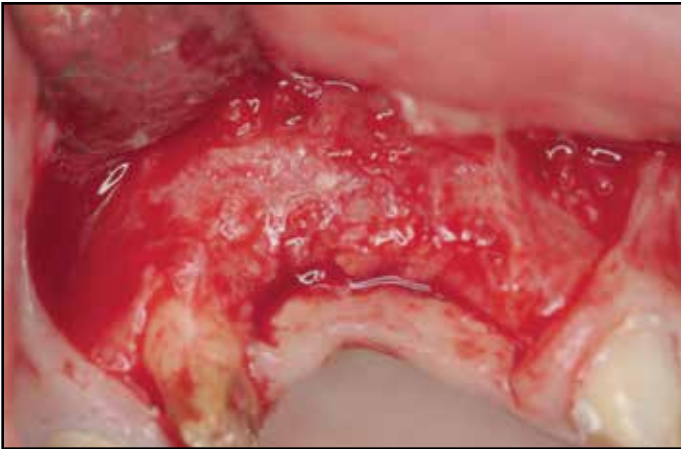


Figure 8: Re-entry demonstrates significant 3-dimensional regeneration of the severe alveolar defect.

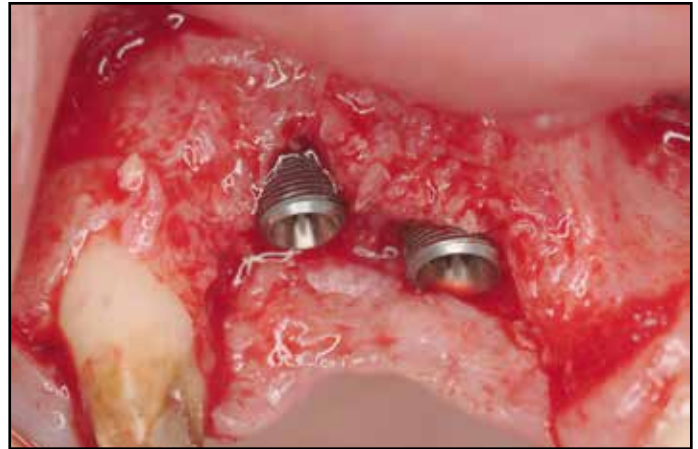


Figure 9: Implant insertion prior to additional bone grafting. Implants were purposely not over-seated, to facilitate restorative treatment and avoid hygienic challenges after restoration.

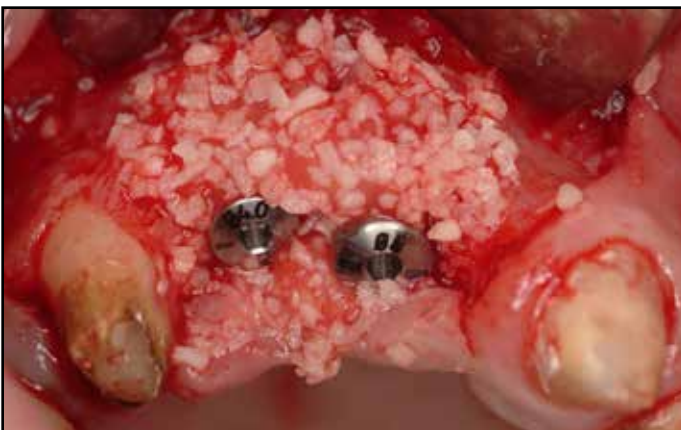

Figure 10: Additional bone grafting, utilizing the same composite graft of rhBMP-2/ACS & FDBA was performed to cover the supra-crestal threads of both implants. Short (2.0mm) healing abutments, rather than cover screws, were utilized to support the overlying flaps and achieve maximum vertical regeneration.

was fabricated to improve retention of a single-unit provisional crown on tooth #6. The provisional FPD was sectioned between #6 and #7 and the patient presented for implant temporization. A minor mucoplasty around the #8 implant was done to facilitate access to the healing abutment and its removal.

Prior to seating the cantilevered provisional restoration, the healing abutment on the #7 implant was painlessly removed and re-tightened without any tactile movement of the implant or discomfort. The provisional restoration, which incorporated pink and tooth-colored composite resin was adjusted and tightened to 15 ncm (Figs. 13-15). The patient was referred back to the restorative dentist to begin definitive restorative therapy in the maxillary anterior sextant.

Restorative therapy entailed conventional crown preparation on the natural teeth, combined with a transfer impression of the two implant fixtures (Fig. 16). A wax-up was per-

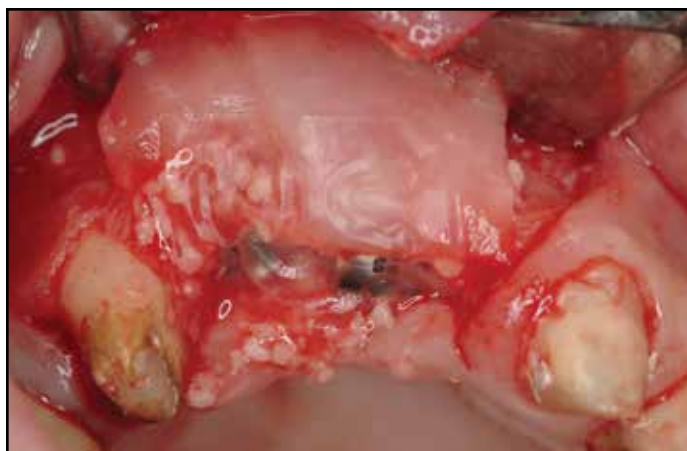

Figure 11: Application of an amnion-chorion membrane over the grafted site.

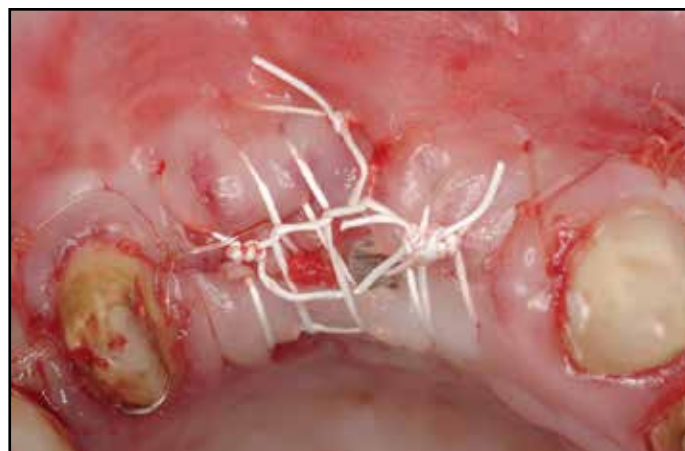


Figure 12: Closure. Note that primary closure was intentionally not achieved. This was the reason for the application of the amnion chorion membrane.

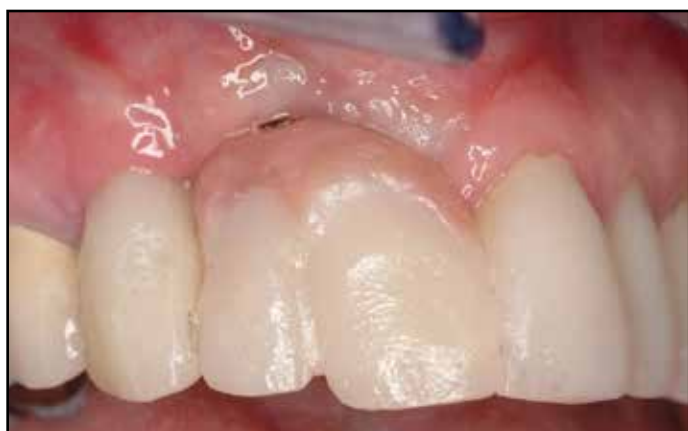

Figure 13: Four months after implant placement, a screw-retained provisional restoration was placed, supported by the implant in the #8 position. This was done following post and core placement in tooth #6 and fabrication of a single, temporary crown on the canine.

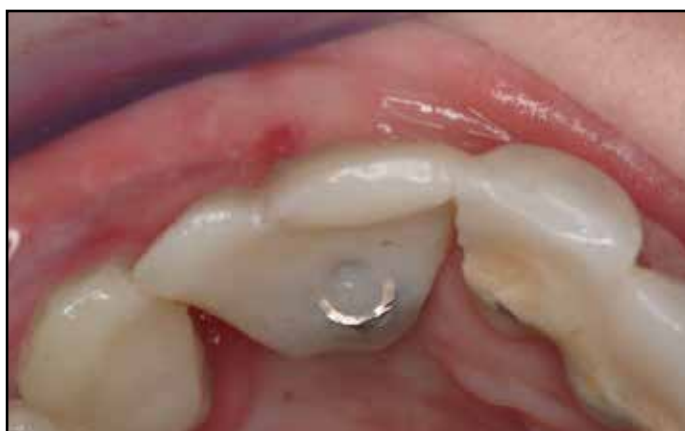

Figure 14: Occlusal view of provisional restoration.

formed of the anticipated restorative outcome (Fig. 17), and computer-assisted abutments (Atlantis; Dentsply) were fabricated for the two implants (Fig. 18). Splinted porcelain fused-to-metal crowns were created for teeth #9-#11, a single PFM crown was fabricated for tooth #6 and splinted, cement-

retained crowns, incorporating pink ceramics were designed for the two implants (Figs. 19, 20A, 20B). A periapical radiograph demonstrated crestal bone present at the level of the implant platforms, suggesting successful regeneration and osseointegration (Fig. 21).

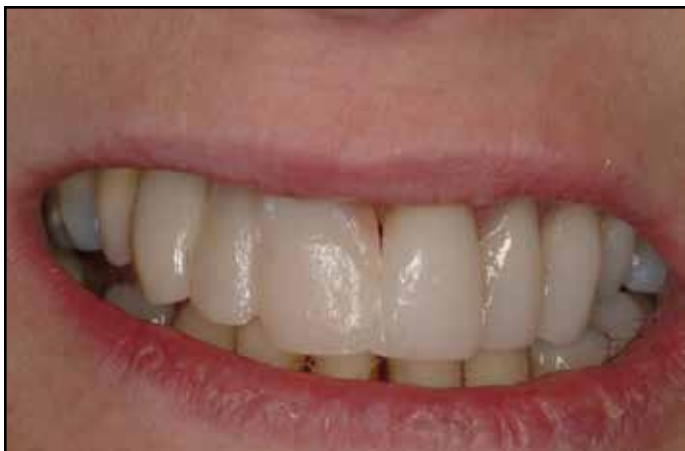

Figure 15: Facial view of provisional restoration.

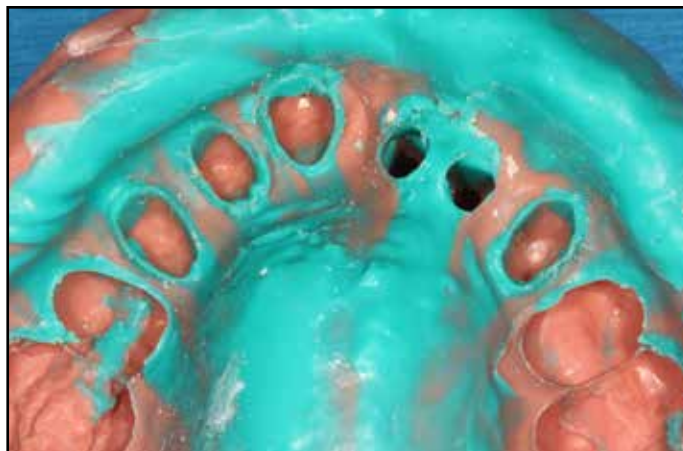

Figure 16: Maxillary polyvinylsiloxane impression.

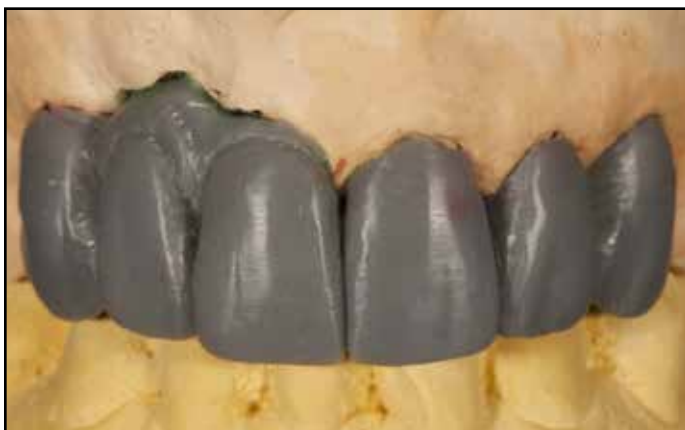

Figure 17: Diagnostic wax-up. Anticipated volume of soft tissue necessary to be compensated for with pink ceramics. Symmetrical tooth contours right and left also planned at the waxing stage of treatment.

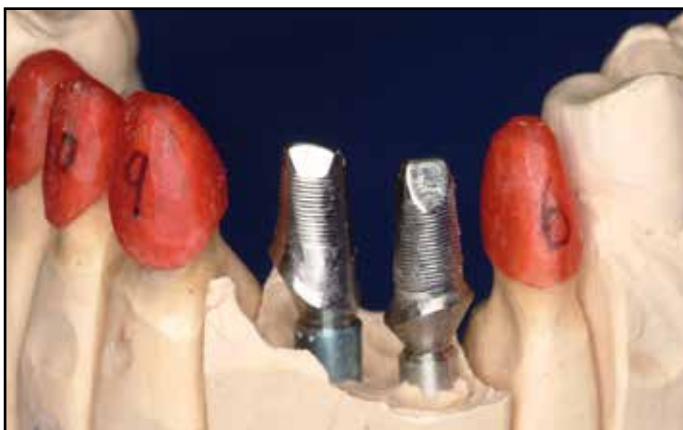

Figure 18: Two CAD/CAM (Atlantis, Dentsply) abutments were digitally-fabricated and seated on two implant replicas. GC resin copings on the adjacent natural teeth are also fabricated.

DISCUSSION

Severe ridge defects, whether associated with tooth loss and/or failed surgical procedures, can present unique and difficult challenges for the implant team. Often, a combined surgical and restorative approach accomplishes greater achievement than a single entity. Pertaining to management of extraction sites, most clinicians prefer either immediate or early implant placement to better position fixture-insertion

prior to the inevitable ridge resorption.¹²⁻¹⁴ When this is not possible, augmentation of the alveolus can prevent significant bone loss.¹⁵⁻¹⁷

The site of tooth #8 was managed with site preservation in this case report. This was the more predictable component of the case presented in this paper. The challenge was regenerating horizontal and vertical height of viable bone in the lateral incisor location, capable of osseointegration. The lack of osseous walls

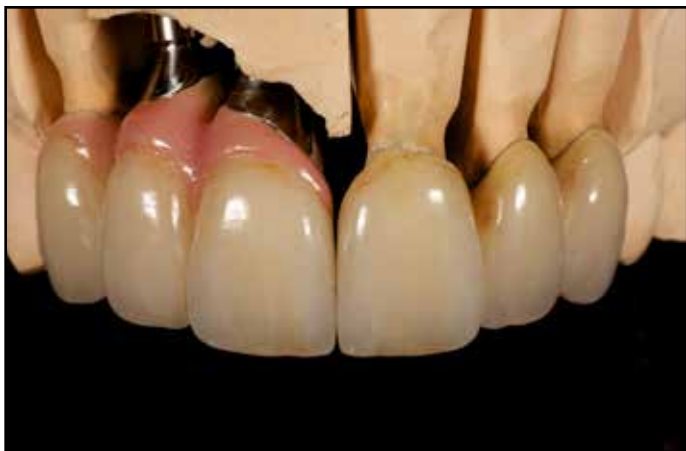

Figure 19: Conventional, PFM crowns are fabricated for the 4 natural teeth in the pre-maxilla. Soft tissue colored ceramics are used on the right canine, as well as the implant-retained restoration to compensate for vertical discrepancies between the right and left sides of the esthetic zone.

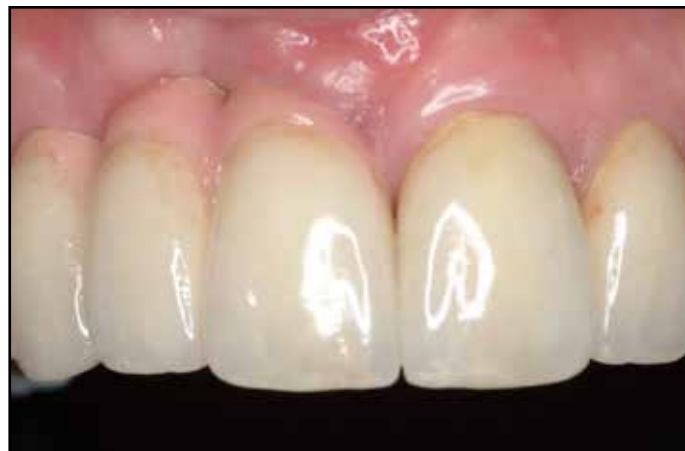

Figure 20a: Final restorations in place.

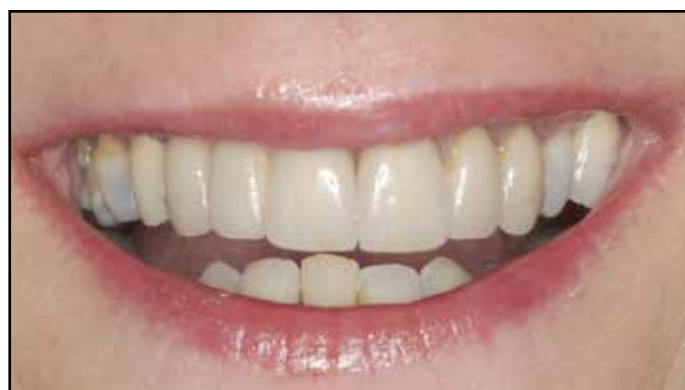

Figure 20b: Patient's natural lip position at full smile.

capable of graft containment and providing a source for vascularity to an inert bone graft was the primary obstacle to overcome. Therefore, a graft with osteoinductive properties, capable of chemotaxis of mesenchymal stem cells from the defect's periphery, as well as differentiation was a requirement for success in the author's opinion. The production of vascular endothelial growth factor (VEGF) from invading cells was also critical for the revascularization of the bone graft an eventual modeling and bone remodeling necessary for the regeneration of vital bone in the defect area. BMP-2 has been shown to increase the osteoinductivity of allograft bone in the animal model.¹⁸ This material has been successful in the regeneration of bone human extraction sockets, capable of osseointegration with titanium implants.^{19,20} The only FDA-approved carrier for rhBMP-2 is an absorbable collagen sponge. The manufacturer guidelines

provide the sponge be "soak-loaded" with the reconstituted protein for at least 15 minutes prior to it's insertion in situ. The claim is that the rhBMP-2 is released from the ACS over an approximately 14 day period. The biggest disadvantage to this delivery method is the near-total lack of space-maintenance of the ACS. Clinicians have reported on incorporating space-providing modalities with rhBMP-2 to compensate for this disadvantage.²¹⁻²³ The addition of particulate bone grafts increases graft volume, but not necessarily stability in situ.

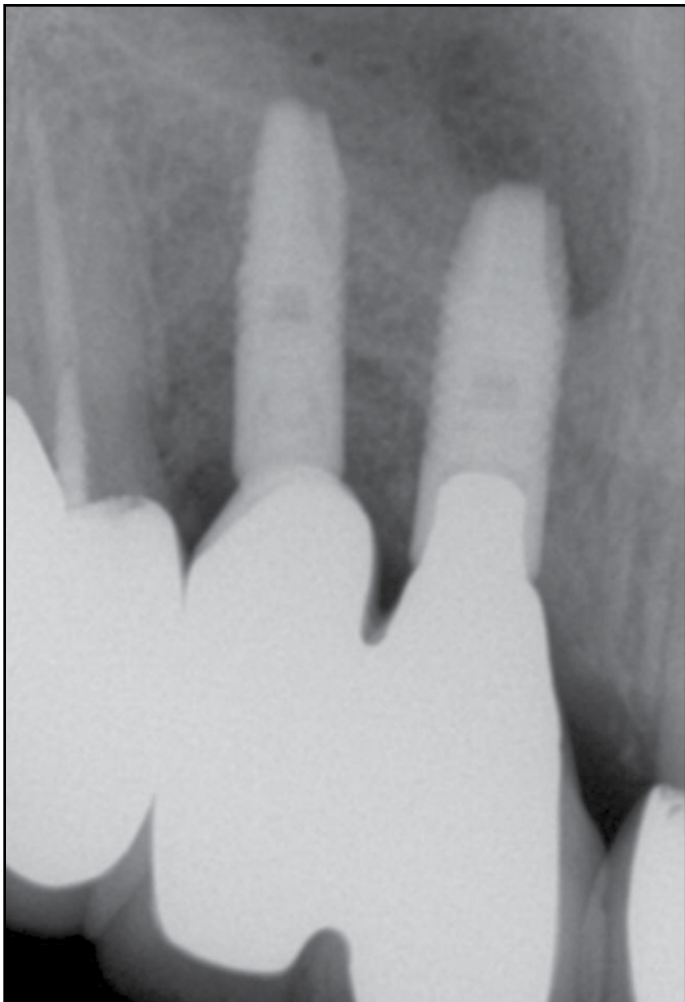


Figure 21: Periapical radiograph taken approximately 2 weeks after delivery of the final restorations. Excellent bone regeneration associated with the two implants, #7 in particular, is appreciated.

A rigid mesh is capable of containing the graft without obstruction of nutrients from the surrounding tissues associated with membranes. The authors have combined mineralized allograft bone with rhBMP-2/ACS to add an osteoconductive component to the inductive rhBMP-2/ACS graft. For purposes of graft containment and more importantly, space-maintenance, a resorbable mesh was implemented to provide

long-lasting support for the underlying regenerative process. The virtue of the resorbable mesh is mainly the biodegradation, facilitating less-invasive flap reflection for implant placement since the mesh and fixation screws/tacks do not require removal. A porous PLGA material, similar to that used in this case, was shown to facilitate bone regeneration in experimental sites in dogs.²⁴ Numerous reports of titanium mesh being used as space-maintenance have been published. The incidence of premature exposures and compromised outcomes have also been reported.²⁵ The resorbable mesh utilized in this case report has demonstrated easier management of early mesh exposures compared to titanium scaffolds in the author's experience.

CONCLUSION

Meeting the patient's esthetic expectations are at least as challenging as the clinical procedures often faced surgically and prosthetically. In order to provide a result the patient will be satisfied with, even when heroic surgical treatment has been accomplished, we must depend on the prosthetic team to make up for any deficiencies surgery did not accomplish. These scenarios could be for example due to the type of defect, loss of adjacent periodontal ligament and existing blood supply, thus resulting in some instances in different bone height and corresponding soft tissues. Among the prosthetic objectives for the final restoration are: duplication of color, shape, translucency and texture. Even when these previous concepts are accomplished, patient's expectations may still not be met, especially when the resulting crown will have a long gingival-incisal anat-

omy. Therefore, to overcome this problem, and with the attempt to have a correct proportion between the final restoration and adjacent teeth, pink porcelain or composite is often utilized, thus enabling us to have the appearance of a normal size tooth with the correct proportion as it relates to adjacent teeth and just as important to be pleasing to the patient's smile.²⁶⁻³⁰ ●

Correspondence:

Dr. Barry P. Levin
7848 Old York Rd.
Elkins Park, PA 19027
(215) 635-0465 phone
(215) 635-2751 fax
aperiodoc@verizon.net

Disclosure

The author reports no conflicts of interest with anything mentioned in this article.

References

- Reich KM, Huber CD, Lippnig WR, Ulm C, Watzek G, Tangl S. Atrophy of the residual alveolar ridge following tooth loss in an historical population. *Oral Diseases* 2011;17:33-44.
- Atwood DA. Postextraction changes in the adult mandible as illustrated by microradiographs of midsagittal sections and cephalometric roentgenograms. *J Prosthet Dent* 1963;13:810-824.
- Paoloantonio M, Doci M, Scarano A, eArchivio D, di Placido G, Tumini V, Piattelli A. Immediate implantation in fresh extraction sockets. A controlled clinical and histological study in man. *J Periodontol*. 2001;72:1560-1571.
- Botticelli D, Berglundh T, Lindhe L. Hard tissue alterations following immediate implant placement in extraction sites. *J Clin Periodontol* 2004;31:820-828.
- Sanz M, Cecchinato D, Ferrus J, Pjetursson EB, Lang NP, Lindhe J. A prospective, randomized-controlled clinical trial to evaluate bone preservation using implants with different geometry placed into extraction sockets in the maxilla. *Clin Oral Impl Res*. 2010;21:13-21.
- Araujo MG, Lijenberg B, Lindhe J. B-tricalcium phosphate in the early phase of socket healing: an experimental study in the dog. *Clin Oral Impl Res*. 2010;21:445-454.
- Iasella JM, Greenwell H, Miller RL, Hill M, Drisko C, Bohra AA, Scheetz JP. Ridge preservation with freeze-dried bone allograft and a collagen membrane compared to extraction alone for implant site development: A clinical and histologic study in humans. *J Periodontol*. 2003;74:990-999.
- Von Arx T, Buser D. Horizontal ridge augmentation using autogenous block grafts and the guided bone regeneration technique with collagen membranes: a clinical study with 42 patients. *Clin Oral Impl Res*. 2006;17:359-366.
- Misch CM, Misch CE. The repair of localized severe ridge defects for implant placement using mandibular bone grafts. *Implant Dent*. 1995;4:261-267.
- Nevins M, Al Hezaimi K, Schupbach P, Karimbux N, Kim DM. Vertical ridge augmentation using an equine bone and collagen block infused with recombinant human platelet-derived growth factor-BB: A randomized single-masked histologic study in non-human primates. *J Periodontol* 2012;83:878-884.
- Bianchini MA, Buttendorf AR, Benfatti CAM, Bez LV, Ferreira CF, de Andrade RF. The use of freeze-dried bone allograft as an alternative to autogenous bone graft in the atrophic maxilla: A 3-year clinical follow-up. *Int J Periodontics Restorative Dent* 2009;29:643-647.
- Evans CDJ, Chen ST. Esthetic outcomes of immediate implant placements. *Clin Oral Impl Res* 2008;19:73-80
- Meltzer AM. Immediate implant placement and restoration in infected sites. *Int J Periodontics Restorative Dent* 2012;32:e169-e173.
- Levin BP. Immediate temporization of immediate implants in the esthetic zone: Case reports evaluating survival and bone maintenance. *Compend Contin. Ed Dent* 2011;32:52-62.
- Barone A, Ricci M, Toneli P, Santini S, Covani U. Tissue changes of extraction sockets in humans: a comparison of spontaneous healing vs. ridge preservation with secondary soft tissue healing. *Clin Oral Impl Res* 2012;0:1-7.
- Perelman-Karmon M, Kozlovsky A, Lilov R. Socket site preservation using bovine bone mineral with and without a bioresorbable collagen membrane. *Int J Periodontics Restorative Dent* 2012;32:459-465.
- Scheyer ET, Schupbach P, McGuire MK. A histologic and clinical evaluation of ridge-preservation following grafting with demineralized bone matrix, cancellous bone chips, and resorbable extracellular matrix membrane. *Int J Periodontics Restorative Dent* 2012;32:543-552.
- Boyan BD, Ranly DM, Schwartz Z. Use of growth factors to modify osteoinductivity of demineralized bone allografts: Lessons for tissue engineering of bone. *Dent Clinics N America* 2006;50:217-228.
- Cochran DL, Jones AA, Lilly LC, Fiorellini JP, Howell H. Evaluation of recombinant human bone morphogenetic protein-2 in oral applications including the use of endosseous implants: 3-year results of a pilot study in humans. *J Periodontol* 2000;71:1241-1257.
- Fiorellini JP, Howell TH, Cochran D, Malmquist J, Lilly LC, Spagnoli D, Toljanic J, Jones A, Nevins M. Randomized study evaluating recombinant human bone morphogenetic protein-2 for extraction socket augmentation. *J Periodontol* 2005;76:605-613.
- Tarnow DP, Wallace SS, Froum SJ, Motroni A, Prasad HS, Testori T. Maxillary sinus augmentation using recombinant bone morphogenetic protein-2/acellular collagen sponge in combination with a mineralized bone replacement graft: A report of three cases. *Int J Periodontics Restorative Dent* 2010;30:139-149.
- Misch CM. Bone augmentation of the atrophic posterior mandible for dental implants using rhBMP-2 and titanium mesh: clinical technique and early results. *Int J Periodontics Restorative Dent* 2011;31:581-589.
- Levin BP. Horizontal alveolar ridge augmentation: the importance of space maintenance. *Compend Contin Ed Dent* 2011;32:12-22.
- Matsumoto G, Hoshino J, Kinoshita Y, Sugita Y, Kubo K, Maeda H, Arimura H, Matsuda S, Ikada S. Evaluation of guided bone regeneration with poly(lactic acid-co-glycolic acid-co-caprolactone) porous membrane in lateral bone defects of the canine mandible. *Int J Oral Maxillofac Implants* 2012;27:587-594.
- Miyamoto I, Funaki K, Yamauchi K, Kodama T, Takahashi T. Alveolar ridge reconstruction with titanium mesh and autogenous particulate bone graft: Computed tomography-based evaluations of augmented bone quality and quantity. *Clin Impl Dent Rel Res* 2012;14:304-311.
- Coachman C, Calamita M. The reconstruction of pink and white esthetics. *Int Dent SA*, 2010;12(3):88-93.
- Coachman C, Salama M, Garber DA, Calamita M, Salama H, Cabral G. Prosthetic gingival reconstruction in a fixed partial restoration. Part 1: Introduction to artificial gingival as an alternative therapy. *Int. J. Periodontics & Restor. Dent*. 2009;29:471-477.
- Salama M, Coachman C, Garber DA, Calamita M, Salama H, Cabral G. Prosthetic gingival reconstruction in a fixed partial restoration. Part 2: Diagnosis and treatment planning. *Int. J. Periodontics & Restor. Dent*. 2009;29:573-581.
- Coachman C, Salama M, Garber DA, Calamita M, Salama H, Cabral G. Prosthetic gingival reconstruction in a fixed partial restoration. Part 3: Laboratory procedures and maintenance. *Int. J. Periodontics & Restor. Dent*. 2010;30:19-29.
- Priest GF, Lindke L. Gingival-colored porcelain for implant-supported prostheses in the aesthetic zone. *Practical Periodontic & Aesthetic Dentistry* 1998;10:1231-1240.