

# The Dermal Apron Technique for Immediate Implant Socket Management: A Novel Technique

BARRY P. LEVIN, DMD\*

## ABSTRACT

With immediate implant placement and provisionalization (IIP) in the esthetic zone, measures to counter hard and soft tissue loss are frequently necessary. To reduce the morbidity associated with bone and connective tissue procurement, various exogenous materials are utilized. The "Dermal Apron Technique" presented in this article demonstrates the use of a composite bone particulate (allograft/xenograft) plus a dermal allograft, adapted around screw-retained temporary crowns and secured within a subperiosteal pouch. The purpose is to augment the thickness of peri-implant mucosa for the purpose of preserving ridge dimensions and preventing mucosal recession. Controlled studies are required to further support its use.

## CLINICAL SIGNIFICANCE

Soft tissue health and harmony are critical for successful implant therapy in the esthetic regions of the dentition. Often, autogenous soft tissue grafts are used to augment peri-implant soft tissues. The Dermal Apron Technique is a method, that in specific situations, obviates the need for autogenous grafting. This reduces treatment time and morbidity associated with procurement of these grafts. The Dermal Apron Technique is used simultaneous with immediate placement and provisionalization and can improve long-term esthetic outcomes for patients.

(J Esthet Restor Dent 28:18–28, 2016)

## INTRODUCTION

Following implant installation, and simultaneous with osseointegration, mucosal attachment occurs. Regardless of implant macro and microtopography, a "biologic width" forms circumferentially around the implant. Abrahamsson and colleagues<sup>1</sup> demonstrated this in the canine model. The junctional epithelium was approximately 2.0 mm in height and the connective tissue dimensions was around 1.0 mm, with an average overall height of peri-implant mucosa of 3.11 to 3.50 mm at 6 months of plaque control. Berglundh and colleagues<sup>2</sup> demonstrated that formation of barrier epithelium and connective tissue maturation between 6 and 12 weeks of transmucosal

healing. These studies evaluated implants placed into healed alveolar bone. Along with the vertical component of biologic width, which is often appreciated as a component of proximal bone levels seen radiographically, a horizontal aspect has profound effects on hard and soft tissue levels. For this reason, investigators have recommended minimal distances between implants and adjacent teeth, as well as adjacent implants.<sup>3–5</sup>

Frequently, implants are placed at the time of extraction. Hammerle and colleagues<sup>6</sup> classified immediate placement as Type I placement. The predictability of immediate implant placement is well-documented.<sup>7,8</sup> Shibly and colleagues<sup>9</sup> showed that immediate implants

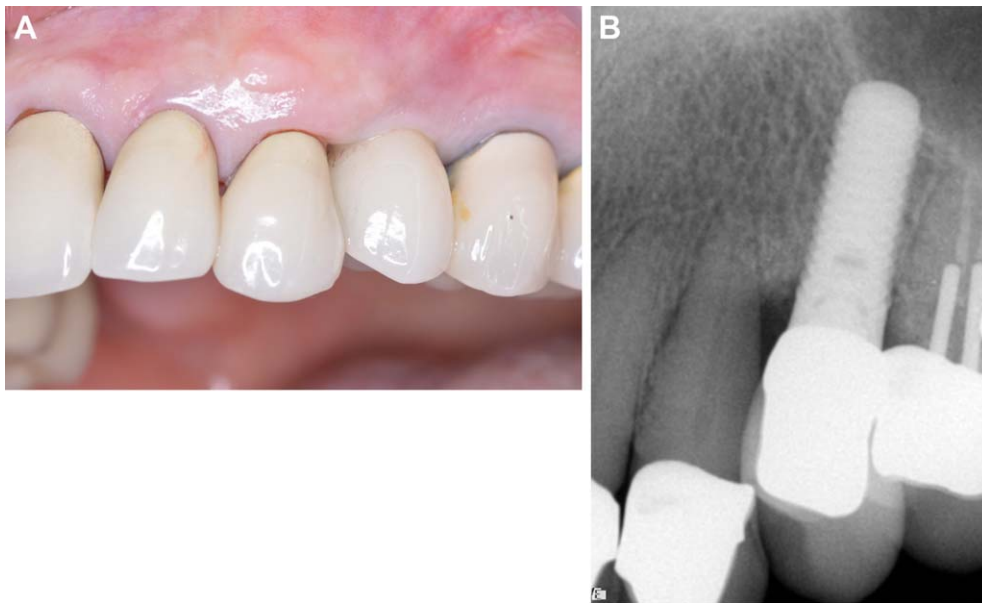
\*Clinical Associate Professor, Department of Graduate Periodontology and Dental Implant Surgery, University of Pennsylvania, Private Practice, 509 York Rd. Jenkintown, PA, 19046, USA. E-mail: Aperiodoc509@gmail.com

can be successful regardless of whether immediate or delayed restorations are delivered. Temporizing implants placed simultaneous with extraction of anterior teeth is well-established scientifically.<sup>10–12</sup> One of several advantages of this technique is the elimination of removable prostheses worn during the osseointegration phase. Another virtue of immediately provisionalizing immediate implants is the inherent soft tissue adaptation around physiologically-contoured restorations, which aids in esthetically-blending restorations within the partially-edentulous segment of the dentition. This can be done with temporary crowns<sup>13</sup> or customized healing abutments.<sup>14</sup>

Confounding predictable success with immediate implant placement and provisionalization (IIP), is the physiologic modeling and remodeling the alveolar ridge undergoes following extraction. Wilson<sup>15</sup> showed predictable resolution of the horizontal defect between implants and socket walls when the distance (HDD) was minimal (1.5 mm). This finding only supports the ability of immediate implants to achieve osseointegration in the coronal region of the extraction socket. It does not account for the horizontal ridge atrophy, which occurs after extraction. In the animal model, Araujo and colleagues<sup>16</sup> demonstrated the failure of immediate implant placement to preserve alveolar ridge dimensions. Botticelli and colleagues<sup>17,18</sup> demonstrated in both dog and human models, significant horizontal resorption at immediate implant sites at 4 months, although these implants were inserted in conjunction with flap-reflection. Patients receiving IIP without any compensatory treatment, i.e., hard or soft tissue grafting, Kan and colleagues<sup>19</sup> and Evans and Chen<sup>20</sup> both demonstrated significant recession and impaired esthetics may occur. It should be pointed out, these authors utilized different implant systems, with different restorative platforms, and these variables cannot be overlooked when evaluating their effects on esthetic outcomes of therapy. Various measures have been proposed to counter ridge resorption and provide long-term esthetics. Obturating the void between the socket walls and implant has been shown in numerous studies.<sup>21,22</sup> Others have demonstrated the efficacy of autogenous soft tissue grafts to prevent facial recession around anterior

implant restorations,<sup>23–25</sup> although several of these patients also demonstrated soft tissue recession. The rationale for using soft tissue grafts in implant therapy includes reducing the probability of postoperative recession, it may also provide adequate soft tissue dimensions for formation of biologic width without compensatory bone resorption. Although techniques have evolved, the morbidity associated with procurement of autogenous soft tissue grafts cannot be completely eliminated.

The use of allogeneic bone in implant and periodontal therapy has eliminated autogenous bone harvesting in the majority of situations formerly requiring secondary sites. Soft tissue allografts have also been used, primarily in periodontal surgery as alternatives to autologous soft tissues. Inert allografts do not contain cells and blood vessels, therefore, leading to significantly slower incorporation at the recipient sites compared to free gingival and subepithelial connective tissue grafts. They must be completely covered by host tissue to avoid sloughing. Because of these shortcomings, dermal allografts have lagged behind autogenous soft tissue grafts in their acceptance in implant therapy. The purpose of this article is to demonstrate a technique, called the “dermal apron,” where a dermal allograft is trimmed and adapted around provisional crowns placed at time of IIP. The graft is placed after obturating the HDD with a composite bone particulate composed of FDBA (freeze-dried, bone allograft) and DBBM (deproteinized bovine bone mineral). A narrow pouch is created between the facial bony wall and periosteum to facilitate insertion of the dermis into this void and secured with resorbable sutures. This subperiosteal pouch is extended only several millimeters, to minimize the amount of separation between the thin facial bone and periosteum, to accommodate the dermal allograft. This subperiosteal pouch is extended only several millimeters, to minimize the vascular detachment from the facial, bundle bone. With a flapless approach, creating a partial-thickness flap increases the risk of soft tissue perforation, therefore, the author elects to position the dermal allograft subperiosteally, although not compromising the thickness of the overlying mucosa.

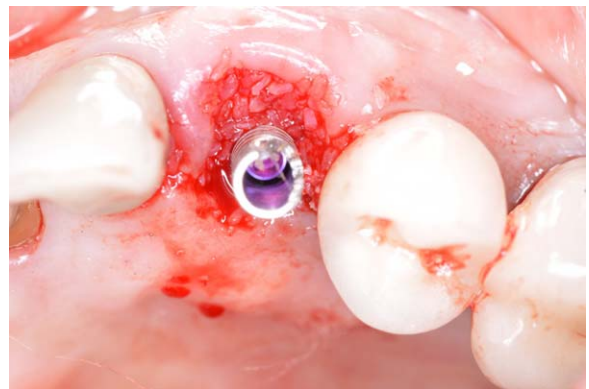

**FIGURE 1.** A, Maxillary left canine presents with root fracture and hypermobility. Tooth #12 has previously been replaced with an implant. B, Preoperative radiograph demonstrating significant bone loss along the distal surface of tooth #11 associated with a longitudinal root fracture.

## CASE SERIES

### Patient 1

A 67-year-old female presented with a root fracture associated with tooth #11 (Figure 1A,B). Following careful extraction without flap reflection, the alveolus was thoroughly debrided with ultrasonic and manual instrumentation. A  $3.6 \times 13.0 \text{ mm}^2$  implant was placed, engaging palatal and apical bone, with primary stability. The gap or HDD between the implant and socket walls was obturated with a composite bone graft composed of four parts FDDBA (Symbios, Dentsply) and one part DBBM (BioOss; Geistlich) (Figure 2). This composite graft was selected to exploit the benefits of both materials. Although both grafts are “osteconductive,” the allograft is expected to be substituted with vital bone, capable of osseointegration. The xenograft is slowly-substituted, if at all, and is used primarily a long-term space maintainer, yet capable of bone apposition onto these particles. The ratio is empirical, but selected by the author to maximize graft replacement whereas limiting ridge diminution, as experienced with allograft exclusively. A temporary abutment was attached to the



**FIGURE 2.** After extraction and implant placement, a modified, temporary abutment is seated and the horizontal void between the implant and the facial socket wall is obturated with a composite graft of FDDBA + DBBM with a 4:1 ratio.

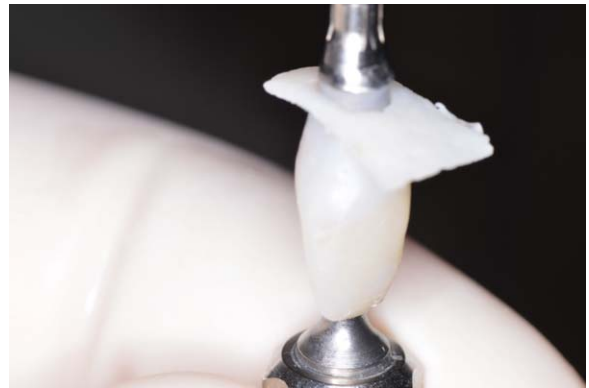implant and a vacuum-formed shell was placed over the temporary abutment and filled with a bis-acryl (Luxatemp) temporary restorative material. After contouring the provisional in vitro to mimic the supragingival anatomy of the extracted tooth (crown), the submucosal contours were deliberately made flat or concave to avoid pressure on the marginal soft tissues. A dermal allograft (PerioDerm; Dentsply) was trimmed and pierced with a disposable, biopsy punch at a diameter slightly smaller than that of the

abutment contours. It was then stretched around the provisional restoration's submucosal portion. It is noteworthy that the connective tissue side of the allograft is oriented in a manner that will contact the periosteum of the peri-implant soft tissues, to encourage revascularization and incorporation (Figure 3). A monofilament, resorbable suture (Monocryl; Ethicon) is used to compress the allograft and secure the mucosa around the temporary crown (Figure 4A). The allograft is advanced "into the pouch" using an internal horizontal mattress suture and then a Figure 8 suture is performed from the facial to palatal mucosa, using the provisional crown as the pier abutment for this suture technique. Tissue blanching initially occurs, which decreases over the course of several minutes postoperatively. In larger sockets, alternative treatment may be indicated. Either a coronally advanced flap, with supraperiosteal dissection may be selected, or an autogenous connective tissue graft can be used, which does not require 100% submerged healing to revascularize. A radiograph is taken to serve as baseline for hard tissue levels and to monitor osseointegration (Figure 4B).

After a healing period of about 10 weeks, the screw-retained, provisional crown is removed for the first time. This is done to record follow-up implant stability quotient (ISQ) and determine if the final restorative phase can commence. At this time, a healthy, thick, keratinized mucosa is evident. The final crown is cement-retained on a CAD/CAM (ATLANTIS; Dentsply) abutment (Figure 5). Figure 6 demonstrates radiographic evidence of proximal bone maintenance 1 year after surgery.

### Patient 2

The second patient is a 37-year-old female who fractured the clinical crown of tooth #8 obliquely (Figure 7A,B). The root was extracted and the socket debrided in the same manner as in the previous case. A 3.6 × 13.0 mm<sup>2</sup> implant was placed in the palatal aspect of alveolus, achieving primary stability, as confirmed with Resonance frequency analysis (RFA), via bone to implant contact apically and palatally. A

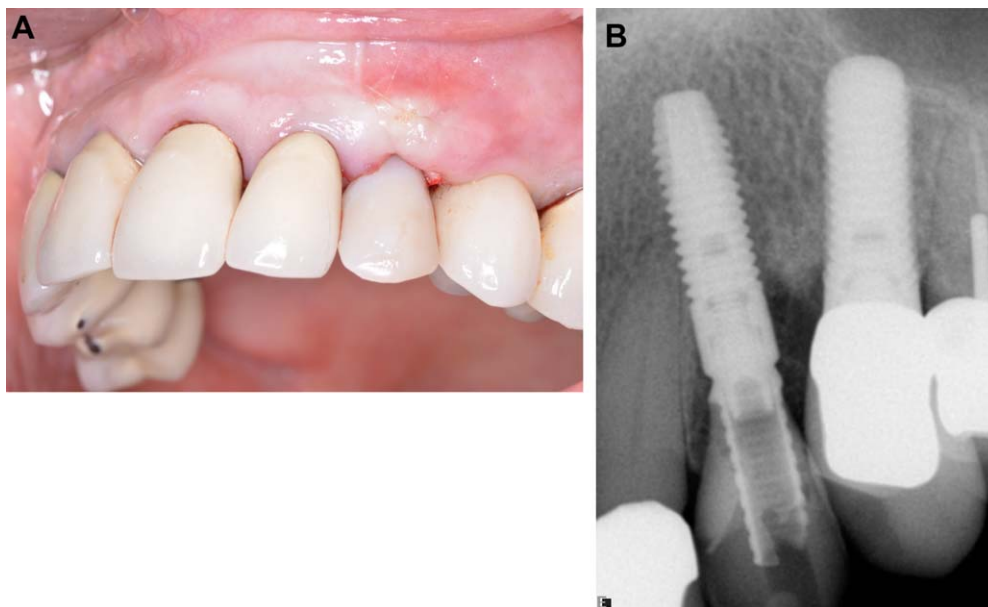


**FIGURE 3.** The dermal allograft material is trimmed and adapted around the submucosal portion of the provisional restoration. The connective side is oriented to be in contact with the peri-implant periosteum.

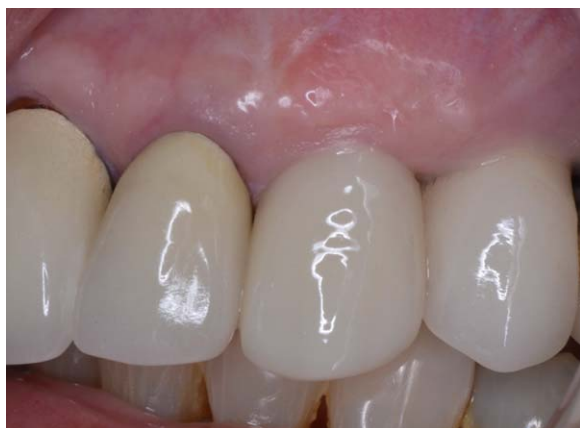wider implant was avoided to avoid proximity to the facial osseous cortex and maintain a void between the implant and the bony wall. The provisional crown was then fabricated in the identical manner as already shown. The dermal allograft was trimmed and "punched," and draped with the "dermal apron" technique, around the provisional crown/abutment. After obturation of the HDD with the same composite, bone particulate graft, the crestal soft tissue was carefully separated from the marginal bone for approximately 5.0 mm with blunt dissection using a small, periosteal elevator and the provisional crown and dermal allograft are seated. A monofilament, resorbable suture was utilized to engage the dermal allograft and secure it with an internal, horizontal mattress suture (Figure 8A), and a baseline radiograph was taken (Figure 8B).

After about 10 weeks, the provisional crown was removed for confirmation of integration prior to referral back to the restorative dentist. At this appointment, physiologically-contoured mucosa, via temporization, was noted, free of inflammation (Figure 9A) and radiographically, bone density appears increased in the area of the residual socket filled with bone graft material (Figure 9B).

At approximately 19 weeks from time of surgery, a screw-retained, ceramo-metal restoration was placed (Figure 10).



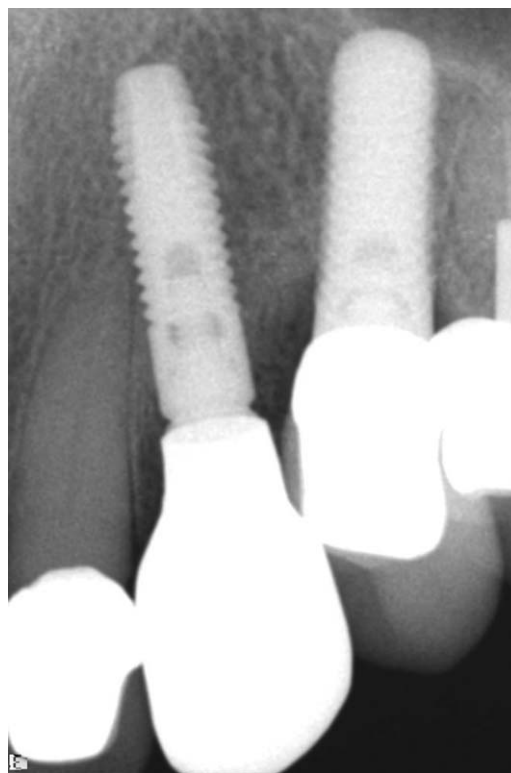
**FIGURE 4.** A, The dermal allograft is “tucked” into the pouch created by blunt dissection between the facial and palatal bone and periosteum and secured with a horizontal mattress suture. B, Postoperative radiograph taken at the completion of immediate placement and provisionalization.



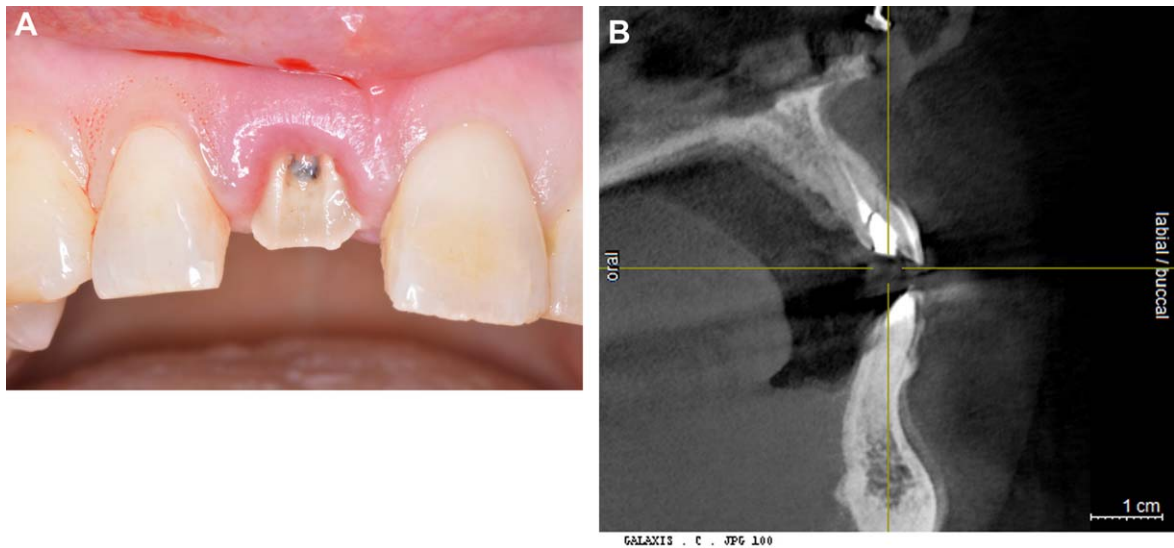
**FIGURE 5.** Final, cement retained restoration surrounded by healthy soft tissues. (Restoration by Dr. E. Litman).

### Patient 3

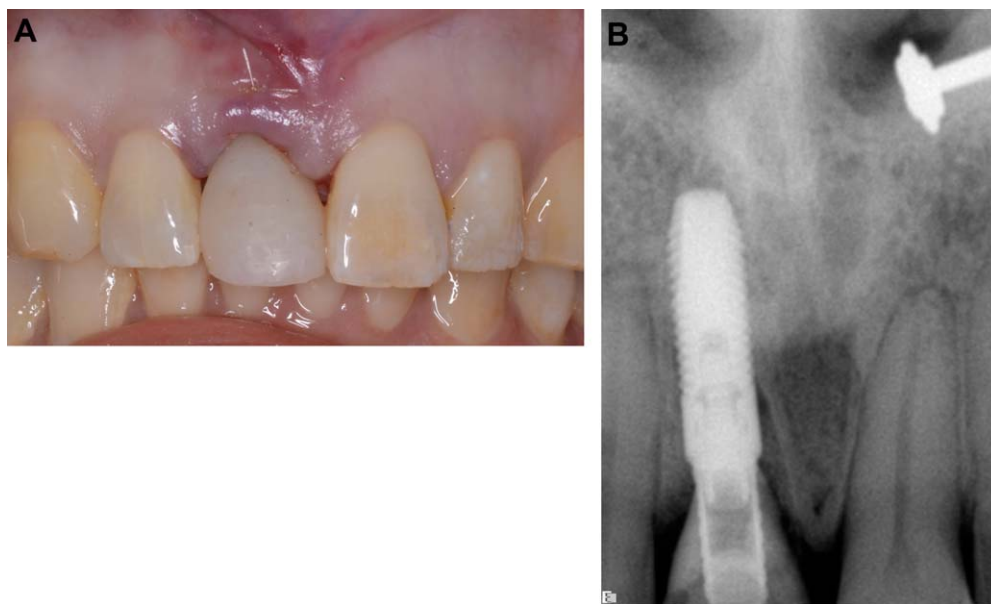
An 87-year-old male presented with a fractured maxillary lateral incisor (Figure 11). Identical treatment, regarding extraction, debridement, and implant placement was performed, placing a  $3.6 \times 13.0 \text{ mm}^2$  implant palatally, engaging bone apical to the base of the socket was performed. RFA confirmed stability and the same composite bone graft was utilized to obturate the



**FIGURE 6.** Radiograph taken approximately 1 year after surgery. Evidence of vertical bone gain is suggested on the distal aspect of implant in the #11 position.



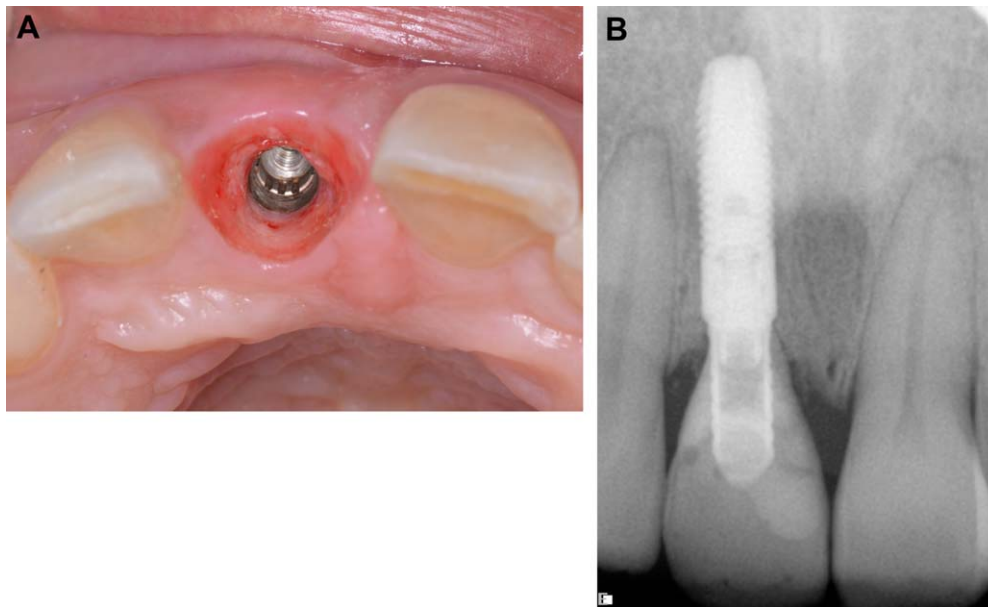
**FIGURE 7.** A, Initial presentation. Tooth #8 is fractured obliquely. B, Cross-sectional view demonstrates the intact labial bone to the level of the root fracture.



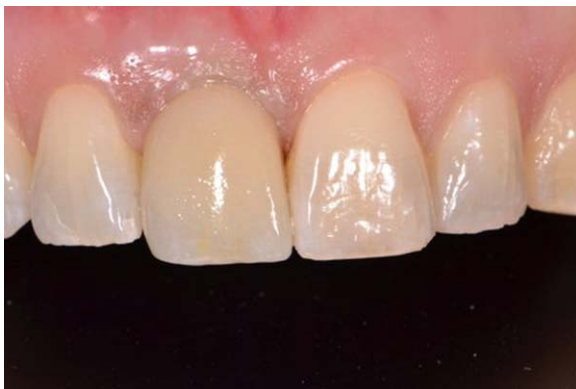**FIGURE 8.** A, The soft tissues are secured with a monofilament, resorbable suture to eliminate voids between the soft tissue and allograft. B, Radiograph taken immediately after IIP and Dermal Apron procedure. The mesial aspect of the socket wall is lightly obturated with bone graft material.

HDD. A screw-retained, provisional crown was fabricated in the same manner as the first two cases. Great care was used to under-contour the submucosal portions of the one-piece abutment/crown. The same dermal allograft previously described was trimmed and adapted via a punch around the temporary restoration. The subperiosteal pouch was created and the dermal

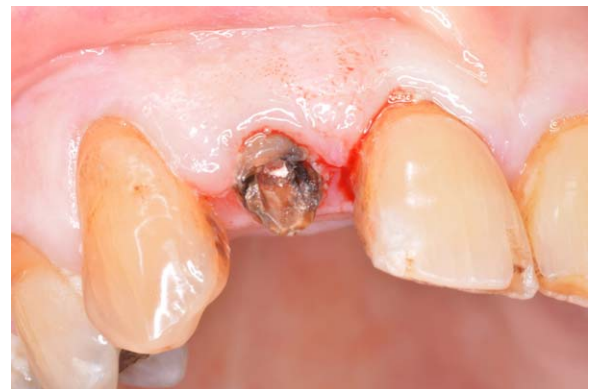graft was inserted and secured with a resorbable suture as already described. Care was taken, as in all cases, to assure no contact existed with mandibular antagonist teeth and a postoperative radiograph was taken (Figure 12). At approximately 10 weeks, the provisional crown was removed to record follow-up ISQ values and refer the patient back to his restorative dentist. The final



**FIGURE 9.** A, At 10 weeks postoperatively, the temporary crown is removed. The physiologic contour created with the provisional restoration is evident without visible ridge narrowing. B, Ten week postoperative radiograph. Bone levels on the adjacent teeth are stable and increased bone density is evident in the area of space occupied by bone graft material.



**FIGURE 10.** Delivery of the final restoration. Note the scalloped, pink peri-implant mucosa. (Restorative therapy by Dr. H. Rosenthaler).



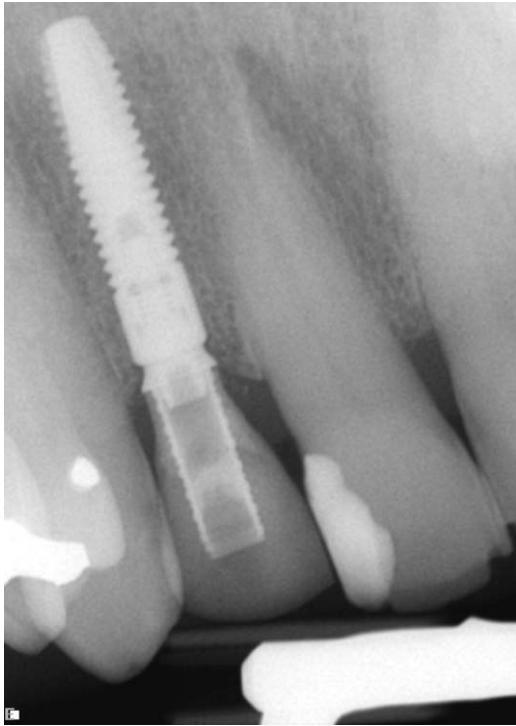
**FIGURE 11.** Preoperative situation demonstrating fractured crown of tooth #7.

crown was cement retained onto a custom abutment (Figure 13A) and radiographic evidence of stable bone levels compared to the postoperative situation is evident (Figure 13B).

## DISCUSSION

The technique presented in this article exploits the biocompatible properties of a particular dermal

allograft. Processing renders this tissue free of cells, reducing the possibilities of foreign body reaction. When adequately submerged, it incorporates within host soft tissues. By thickening peri-implant mucosa, the soft tissue dimensions are increased. The establishment of biologic width coronal to the alveolar crest likely reduced hard tissue loss in healed sites, as demonstrated by Linkevicius. Using a different dermal allograft (Alloderm; BioHorizons), Linkevicius and colleagues.<sup>26</sup> showed peri-implant soft tissues thinner than 2.0 mm resulted in significantly greater marginal



**FIGURE 12.** Radiograph taken immediately postsurgery.

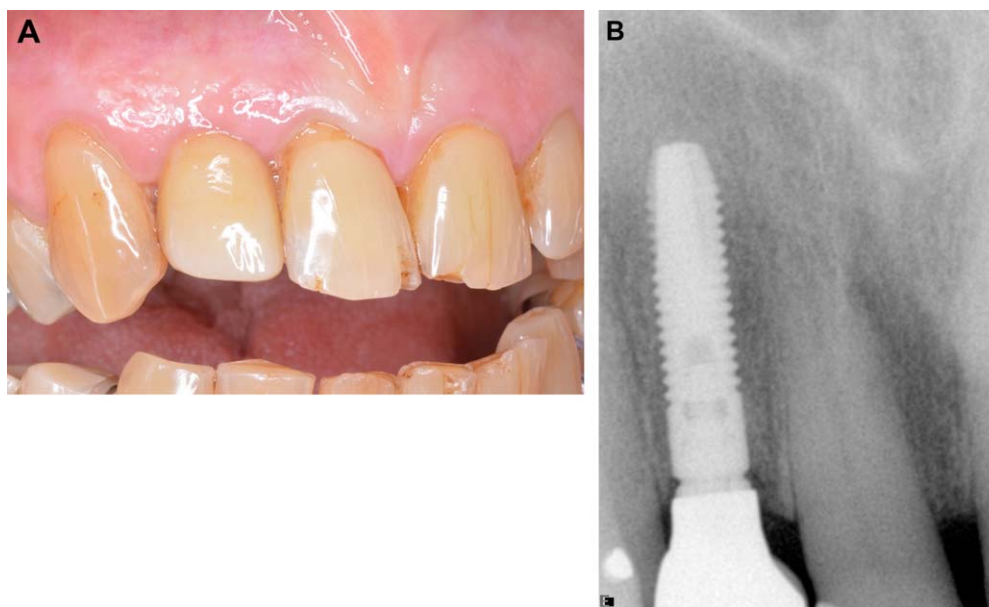
bone loss compared to those implants surrounded by naturally thicker ( $>2.0$  mm) mucosa and implants augmented with a dermal allograft. Their study evaluated implants placed into healed sites, warranting caution when extrapolating these results compared to the present case series, where immediate implants are placed. The effect of soft tissue thickness on peri-implant bone was demonstrated by Berglundh and Lindhe.<sup>27</sup> These investigators surgically resected peri-implant soft tissue and found histologically that marginal bone was located apical to the sites not undergoing soft tissue thinning. Establishment of soft tissue biologic width results in the sacrifice of osseous tissue to preserve this soft tissue barrier. The dermal apron technique attempts to increase the thickness of supra-alveolar soft tissue, with the desired goal of preserving bone after the maturation of the soft tissue attachment to immediately-placed implants.

In esthetically-critical areas of the dentition, such as maxillary anterior teeth, minimal recession may result in catastrophic outcomes. In partially-edentulous patients, any gingival asymmetry may lead to patient dissatisfaction and treatment failure. Measures to avoid

long-term recession should always be taken at the initiation of therapy. This process starts with proper diagnosis. Patients with pre-existing gingival asymmetry, facial bone defects and active, purulent, infection with apical bone loss are some of the relative contra-indications for immediate implant placement and provisionalization (IIP). When conditions permit IIP, measures such as cone-beam, computerized tomography (CBCT) to evaluate the presence of facial bone, occlusal analysis to confirm temporization without contact with antagonist teeth and symmetrical soft tissue contours, may lead surgeons to perform IIP. In patients with thin biotypes, it still may be efficacious to utilize subepithelial, connective tissue grafts versus dermal allografts. This allows a portion of the subepithelial, connective tissue graft (SECTG) to remain exposed and still incorporate and augment soft tissue dimensions. The literature supports the use of SECTG in immediate implant therapy, and should still be considered the ideal treatment when adequate palatal mucosa is available and the patient is receptive to this additional surgical step. When it is anticipated that a dermal allograft, as used in the “dermal apron” technique, will be completely covered with soft tissues, it may serve as an excellent substitute for SECTG and reduce patient morbidity. The use of dermal allografts in immediate implant therapy is not unique.<sup>28</sup> That case report showed exfoliation of the exposed portion of a dermal allograft, with successful bone augmentation around an immediate implant. In the current technique, the dermal allograft is used as both a barrier (GBR) and soft tissue thickening agent.

The importance of obturating the HDD with a particulate graft capable of substitution with vital bone, yet with a portion capable of achieving long-term stability is critical. Chen and colleagues<sup>29</sup> showed the reduction in ridge resorption when immediate implants were combined with regenerative therapy compared to ungrafted controls. In the animal model, Barone and colleagues<sup>30</sup> demonstrated significantly greater ridge preservation when immediate implants were combined with regenerative treatment compared to controls. With excessive bone loss, soft tissue recession can be expected. Recently, Parpaiola and colleagues<sup>31</sup> demonstrated deeper proximal probing depths and





**FIGURE 13.** A, Final, screw-retained crown in place. Healthy, thick, peri-implant mucosa is present. (Restorative therapy by Dr. S. Morris). B, Final restoration is delivered and the radiograph demonstrates proximal bone at the fixture level and in a slightly more coronal location along the proximal root surfaces.

narrower dimensions of keratinized mucosa for single-implants compared to natural teeth. Compensatory augmentation procedures may be indicated to counter long-term esthetic compromises related to physiologic bone modeling following extraction and formation of biologic width around implants. This may reduce the incidence of esthetic failure over time.

## CONCLUSION

The combination of proper implant selection, meticulous contouring of the provisional crown(s), bone and soft tissue augmentation with exogenous biomaterials and proper treatment planning has resulted in predictable and esthetic outcomes in patients requiring immediate implant placement and provisionalization in maxillary anterior sites. With proper case selection, an acellular, dermal allograft may fulfill criteria of serving as both a collagen membrane (GBR) and soft tissue thickening agent when the “Dermal Apron Technique” is utilized in immediate implant and provisionalization (IIP) in the maxillary anterior region. This case series features three examples of over 40 patients treated with this modality by the author. The maximum follow up time

for these patients is approximately 18 months. The three cases presented in this article have all been in function with the final restorations for at least 6 months. As this is a technique developed in a private practice setting, and the majority of treated patients were followed retrospectively, no pretreatment clinical measurements were made regarding dimensions of the ridge, incisal-apical length of crowns. This is information that could serve to further support or refute the use of the dermal apron technique.

None of the patients treated with the dermal apron technique, or their restorative dentists, have presented for treatment of post-operative mucosal recession or esthetic dissatisfaction.

Further research is necessary to further the support of the Dermal Apron Technique for predictable outcomes.

## DISCLOSURE

The author does not have any financial interest in the companies whose materials are included in this article.

## REFERENCES

1. Abrahamsson I, Berglundh T, Wennstrom J, Lindhe J. The peri-implant hard and soft tissues at different implant systems. A comparative study in the dog. *Clin Oral Implants Res* 1996;7:212–9.
2. Berglundh T, Abrahamsson I, Welander M, et al. Morphogenesis of the peri-implant mucosa: an experimental study in dogs. *Clin. Oral Implants Res.* 2007; 18:1–8.
3. Tarnow DP, Cho SC, Wallace SS. The effect of inter-implant distance on the height of inter-implant bone crest. *J Periodontol* 2000;71:546–9.
4. Degidi M, Novaes AB, Nardi D, Piattelli A. Outcome analysis of immediately placed, immediately restored implants in the esthetic area: the clinical relevance of different interimplant distances. *J Periodontol* 2008;79: 1056–61.
5. Chang M, Wennstrom JL. Longitudinal changes in tooth/ single-implant relationship and bone topography: an 8-year retrospective analysis. *Clin Implants Dent Relat Res* 2012; 14(3):388–94.
6. Hämmerle CHF, Chen ST, Wilson TG Jr. Consensus statements and recommended clinical procedures regarding the placement of implants in extraction sockets. *Int J Oral Maxillofac Implants* 2004;19(Suppl):26–8.
7. Tehemar S, Hanes P, Sharawy M. Enhancement of osseointegration of implants placed into extraction socket of healthy and periodontally diseased teeth by using graft material and ePTFE membrane, or a combination. *Clin Implant Dent Relat Res* 2003;5:193–211.
8. Vanden Bogaerde L, Rangert B, Eng M, Wendelhag I. Immediate/early function of Branemark system TiUnite implants in fresh extraction sockets in maxillae and posterior mandibles: an 18-month prospective clinical study. *Clin Implants Dent Relat Res* 2005;7(Suppl 1):121–30.
9. Shilbly O, Kutkut A, Patel N, Albandar JM. Immediate implants with immediate loading vs conventional loading: 1-year randomized clinical trial. *Clin Implants Dent Relat Res* 2012;14(5):663–71.
10. den Hartog L, Raghoobar GM, Stellingsma K, Vissink A, Meijer HJA. Immediate nonocclusal loading of single implants in the aesthetic zone: a randomized clinical trial. *J Clin Periodontol* 2011;38:186–94.
11. Donati M, La Scala V, Billi M, et al. Immediate functional loading of implants in single-tooth replacement: a prospective clinical multicenter study. *Clin Oral Implants Res* 2008;19:740–8.
12. Noelken R, Kunkel M, Jung BA, Wagner W. Immediate nonfunctional loading of nobelperfect implants in the anterior dental arch in private practice – 5-Year Data. *Clin Implants Dent Relat Res* 2012;1–11.
13. Schoenbaum TR, Chang Y-Y, Klokkevold PR, Snowden JS. Abutment emergence modification for immediate implant provisional restorations. *J Esthet Restor Dent* 2013;25:103–7.
14. Becker W, Doerr J, Becker BE. A novel method for creating an optimal emergence profile adjacent to dental implants. *J Esthet Restor Dent* 2012;24:395–401.
15. Wilson TG, Schenk R, Buser D, Cochran D. Implants placed in immediate extraction sites: a report of histologic and histometric analyses of human biopsies. *Int J Oral Maxillofac Implants* 1998;13:333–41.
16. Araujo MG, Sukekava F, Wennstrom JL, Lindhe J. Ridge alterations following implant placement in fresh extraction sockets: an experimental study in the dog. *J Clin Periodontol* 2005;32:645–52.
17. Botticelli D, Berglundh T, Lindhe J. Resolution of bone defects of varying dimension and configuration in the marginal portion of the peri-implant bone. An experimental study in the dog. *J Clin Periodontol* 2004;31:309–17.
18. Botticelli D, Berglundh T, Lindhe J. Hard-tissue alterations following immediate implant placement in extraction sites. *J Clin Periodontol* 2004;31:820–8.
19. Kan JYK, Rungcharassaeng K, Lozada JL, Zimmermen G. Facial gingival tissue stability following immediate placement and provisionalization of maxillary anterior single implants: a 2- to 8-year follow-up. *Int J Oral Maxillofac Implants* 2011;26:179–87.
20. Evans CDJ, Chen ST. Esthetic outcomes of immediate implant placements. *Clin Oral Implants Res* 2008;19:73–80.
21. Tarnow DP, Chu SJ, Salama MA, et al. Flapless postextraction socket implant placement in the esthetic zone: Part 1. The effect of bone grafting and/or provisional restoration on facial-palatal ridge dimensional change—a retrospective cohort study. *Int J Periodontics Restorative Dent* 2014;34:323–31.
22. Araujo MG, Linder E, Lindhe J. Bio-Oss Collagen in the buccal gap at immediate implants: a 6-month study in the dog. *Clin Oral Implants Res* 2011; 22:1–8.
23. Chen ST, Darby IB, Reynolds EC, Clement JG. Immediate implant placement postextraction without flap elevation. *J Periodontol* 2009;80:163–72.
24. Grunder U. Crestal ridge width changes when placing implants at the time of tooth extraction with and without soft tissue augmentation after a healing period of 6 months: report of 24 consecutive cases. *Int J Periodontics Restorative Dent* 2011;31:9–17.
25. Yoshino S, Kan JYK, Rungcharassaeng K, et al. Effects of connective tissue grafting on the facial gingival level following single immediate implants placement and provisionalization in the esthetic zone: a 1-year randomized controlled prospective study. *Int J Oral Maxillofac Implants* 2014;29:432–40.

26. Linkevicius T, Puisys A, Linkeviciene L, et al. Crestal bone stability around implants with horizontally matching connection after soft tissue thickening: a prospective clinical trial. *Clin Implants Dent Relat Res* 2013;1–12.
27. Berglundh T, Lindhe J. Dimension of the peri-implant mucosa. Biological width revisited. *J Clin Periodontol* 1996; 23:971–3.
28. Fowler EB, Breault LG, Rebitski G. Ridge preservation utilizing an acellular dermal allograft and demineralized freeze-dried bone allograft: part II. Immediate endosseous implant placement. *J Periodontol* 2000;71:1360–4.
29. Chen ST, Darby IB, Reynolds EC. A prospective clinical study of non-submerged immediate implants: clinical outcomes and esthetic results. *Clin Oral Implants Res* 2007; 18:552–62.
30. Barone A, Ricci M, Calvo-Guirado JL, Covani U. Bone remodeling after regenerative procedures around implants placed in fresh extraction sockets: an experimental study in the Beagle dogs. *Clin Oral Implants Res* 2011;22:1131–7.
31. Parpaiola A, Cecchinato D, Toia M, et al. Dimensions of the healthy gingival and peri-implant mucosa. *Clin Oral Implants Res* 2015;26:657–62.

---

Reprint requests: Barry P. Levin, DMD, Department of Graduate Periodontology and Dental Implant Surgery, Private Practice, 509 York Rd., Jenkintown, PA 19046, USA; Tel.: 215-635-0465; Fax: 215-885-3407; email: Aperiodoc509@gmail.com